

implants

international magazine of oral implantology

2²⁰¹⁷

reprint

Augmentation and defect filling in oral surgery

Henriette Lerner

dentis

Augmentation and defect filling in oral surgery

A multicentre non-interventional study

Author: Henriette Lerner, Germany

Introduction

There is considerable demand for bone replacement and augmentation materials in the field of dental medicine, especially in oral and maxillofacial surgery. A wide variety of biological and synthetic replacement materials is now available. In recent years synthetic substances containing calcium and phosphate have been developed. These require minimal effort, present no practical problems and can be used efficiently and economically. They are usually accepted by the body without problems; their tissue tolerability is excellent and they are neither locally nor systemically toxic. Unlike materials of biological origin they do not pose any risk of infection or sensitisation. In all cases it is of course necessary to take into account the individual hard tissue situation at the site at which bone regeneration material is to be used. A product that is easy to apply is especially useful for filling smaller defects; CERASORB® Paste, which has been available for some time, is such a product.

Tolerability (n = 41)

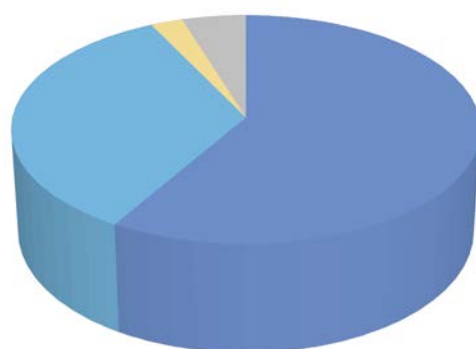


Fig. 1: Overall assessment of tolerability by the dentist carrying out treatment.

very good
good
satisfactory
unsatisfactory
no answer

The aim was to perform a non-interventional study to evaluate its use by as many independent users as possible; handling and usefulness were to be studied in different oral surgical indications under everyday conditions in different dental practices.

Material and methodology

An account is given of experience with the use of the β -tricalcium phosphate preparation CERASORB® Paste within a multicentre study. It was intended that dental practices throughout Germany, independent from one another, participate. Goal and methods were defined in an observation plan to ensure that the procedure was consistent. All results were entered on prepared recording sheets. Because of the non-interventional nature of this study, no particular therapeutic or application plan was imposed; users were instead referred to the instructions given in the information for use. Patients aged between 18 and 70 years with the following pre-operative diagnoses or indications were to be enrolled in the study:

- alveolar defect
- apicoectomy
- preparation of implant bed
- post exstirpational cyst filling
- internal sinus lift
- periodontal pocket
- further indications equivalent to those already mentioned

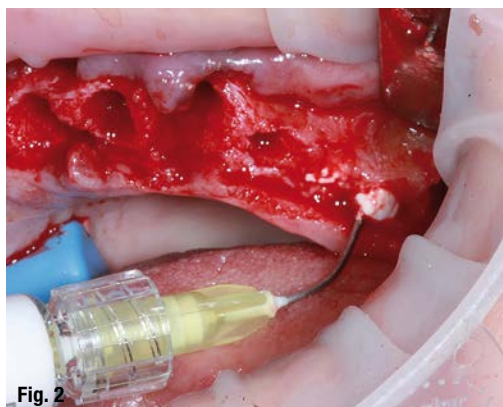
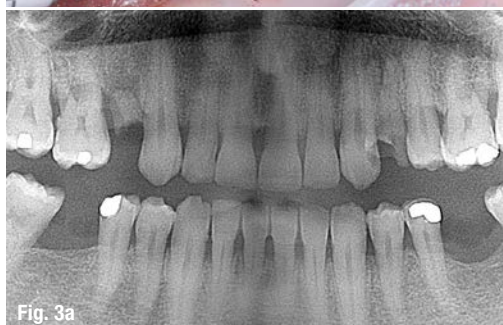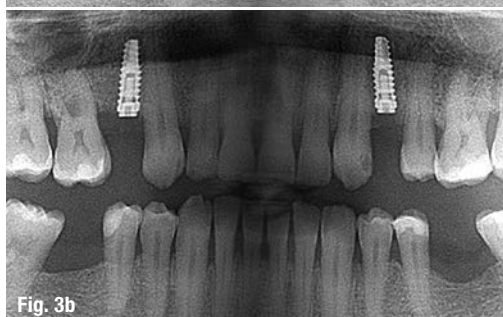Patients were not to be included in the study if they were unsuitable for bone regeneration procedures because of general medical exclusion criteria or local inflammation in the surgical area, or if they regularly took medication that could influence wound healing (such as cortisone preparations and immunosuppressants).

Tab. 1: Pre-operative diagnoses

Pre-operative diagnosis	Number (n = 41)
Apicoectomy	7
Cyst	6
Periodontitis/periimplantitis	6
Bone defect	4
Augmentation for implantation	4
Filling of alveolar sockets after extraction	3
Tooth loosening/implant loosening	2
Intrabony pocket	2
Augmentation for implantation	2
Tooth not worth maintaining	2
Implant loss	1
Incomplete root canal filling	1
Bone sequestrum	1

The subject of the study was CERASORB® Paste (curasan AG, Kleinostheim, Germany), a three-phase bone regeneration material in paste form containing powdered β -TCP in a matrix of hyaluronic acid and methyl cellulose; it is based on CERASORB®, a well-known product that has been in use for many years. During the process of manufacturing β -TCP, CERASORB® ceramic particles with an average size of 63 μ m are created by sintering and grinding. These are mixed with an aqueous polymer solution in the ratio (by weight) 70% ceramics and 30% polymer solution. When using this product, as in all augmentation procedures, it is important to ensure that all soft tissue is completely removed so that it is possible for the paste to make direct contact with bone; in the process heavy bleeding should be stopped to make it possible for the material to adhere well to the bone.

After history-taking and an initial examination (documented with X-ray images if possible) with explanation of the procedure and consent to the operation, records were made of the treatment and follow-up examinations that had been performed; follow-up examinations were carried out one to two weeks postoperatively, after three, six and twelve months and later if necessary depending on the heal-

**Fig. 2****Fig. 3a****Fig. 3b****Fig. 2:** Application of CERASORB® Paste in an extraction socket.**Fig. 3a:** Case example. Patient: HM, male, 51 years, remainder of teeth 14 and 24. Orthopantomograph (OPG) of initial state, extraction and filling of sockets with paste on 18 November 2014.**Fig. 3b:** Implantation on both sides on 1 April 2015, postoperative OPG four and a half months after augmentation with CERASORB® Paste and placement of two implants.

ing and bone-regeneration process. The dentist carrying out the treatment was responsible for deciding when and how frequently follow-up examinations occurred. When explaining the procedure to the patient it is not necessary to mention the possible complications of bone harvesting, or problems relating to rejection reactions and potential risk of allergic sensitisation and infection, as is the case with biological materials.

Parameters for judging successful bone healing with CERASORB® Paste ["effectiveness parameters"]:

- bone structure as seen in follow-up X-rays
- current clinical status (such as state of mucous membranes, suture dehiscence)
- bone situation at implantation
- global evaluation of effectiveness/therapeutic success by the dentist carrying out treatment
- cases in which treatment was terminated or changed because of lack of effectiveness

After the study had been completed, the recording sheets were examined centrally to check completeness and subjected to quality control. After double

Tab. 2: Treated sites/frequencies: (n = 77 in 41 patients)

1 st quadrant	2 nd quadrant	3 rd quadrant	4 th quadrant
11 – 2	21 – 5	31 – 0	41 – 1
12 – 4	22 – 2	32 – 0	42 – 0
13 – 1	23 – 3	33 – 0	43 – 0
14 – 6	24 – 7	34 – 1	44 – 2
15 – 3	25 – 4	35 – 2	45 – 1
16 – 4	26 – 5	36 – 5	46 – 5
17 – 4	27 – 4	37 – 3	47 – 1
18 – 2	28 – 0	38 – 0	48 – 0
Σ = 26 (33.77 %)	Σ = 30 (38.96 %)	Σ = 11 (14.28 %)	Σ = 10 (12.99 %)

data entry a purely descriptive evaluation was carried out as is usual for studies of this kind.

Results

Altogether twelve dental practices and dental surgery practices from all over Germany took part. The observation period (from the first treatment day of the first patient to the last treatment day of the last patient) extended from August 2013 to June 2015. It was possible to evaluate recording sheets on 41 patients (19 female, 22 male) aged 22 to 74 years (mean age: 55.2 years, median age: 57 years). Patients with certification of appropriate pre-operative diagnoses or indications were included in the study. In the process it became apparent that CERASORB® Paste was used with very different diagnoses in daily routine work:

A total of 23 concomitant illnesses in 16 patients were reported. The most frequent were hypertension in six patients, allergic reactions in four patients and

tinnitus, rheumatism and Tension Neck Syndrome in two patients each. Four participants were smokers. Six patients were taking nine different medications altogether, the most frequent being 100 mg aspirin in three cases. Augmentation or defect filling was carried out at a total of 77 sites in the 41 patients (Table 2).

CERASORB® Paste was most often used in 1 ml volumes (n=31 patients [76%]) (range: 0.5 – 3.0 ml). In none of the cases was autologous cancellous bone mixed in. Twenty membranes were used in 18 cases (19 resorbable, one non-resorbable). Complete primary wound closure was achieved in 36 cases.

Antibiotics were applied in 24 cases (58%), only pre-operatively in five patients and only postoperatively in 19 patients. The most frequently-used antibiotics were clindamycin (in 20 patients) and amoxicillin (n = 2). They were taken for a duration of five to ten days, the mean and most frequent duration being ten days. The surgical operations and postoperative periods were free from complications.

At the clinical follow-up examination performed one to two weeks after the operation, an evaluation was made of the state of the membranes, the extent of inflammation and patient compliance. The soft-tissue healing was classified as very good or good in 93 % of cases (see Table 3). The membrane situation was also classed as very good in 36 % of cases and as good in 51 %. These results were certainly also due to good patient compliance.

26 patients (= 63 %) indicated that they rinsed regularly; this was done by far the most frequently (in 18 cases) with chlorhexidine. It was suggested to the dentists carrying out the treatment that clinical evaluations of the progress and success of new bone formation (by comparison with the initial state on the day of the operation) should be made after about three, six, nine and twelve months. Analysis of the results revealed undisturbed healing and a continual decrease in the amount of synthetic bone regeneration material with time. After twelve months, bone regeneration material was still visible in five patients

Tab. 3: Follow-up examination after one to two weeks

	Number				Mean(1-3)
	Very good (1)	Good (2)	Satisfactory (3)	No answer	
Evaluation of soft-tissue healing [n=41 patients]:	24 (59 %)	14 (34 %)	3 (7 %)		1.48
Evaluation of membrane [n=18 patients]:	6 (33.3 %)	11 (61.1 %)	0	1 (5.6 %)	1,64

(12.2%). Abnormalities were reported in four patients: in two cases, seromas were found at the three-month examination. At the follow-up operation which was necessary, neither augmentation material nor newly-formed bone was found. Augmentation was therefore repeated. After six months, one patient did not have the necessary primary stability for the planned implant. After nine months, another patient showed radiolucency following placement of two implants at #35 and #37. It was found that, in the vast majority of cases, the treatment was complete after a little more than six months; the defects in the above-mentioned patients also healed somewhat later without problems.

The dentist carrying out the treatment then gave a final summarising assessment of the success of the treatment and the tolerability of the materials used. This assessment was made at the last observation point/last appointment of the patient at the dental practice in each case. If the "very good" and "good" judgements are added together, the results for effectiveness are almost 80% and for tolerability are over 90% (see Table 4, final evaluation of the defect filling/augmentation).

Handling and healing were also judged to be very good or good in most cases. The rate of complications can be considered low and not abnormal; it decreased continually with time.

Discussion

In the first few years after the introduction of β -TCP CERASORB®, many users still tended to mix this bio-ceramic product with autologous bone before using it. This became progressively less common because of all the positive experience gained from using the product on its own. As long ago as 2000, Szucs and colleagues reported that, in 52 patients with different dental or surgical indications, the implanted β -TCP had been completely transformed into bone within twelve months and that bone tissue stable enough to hold implants had formed within four to six months.¹ They came to the conclusion that it is not necessary to use autologous bone for a sinus lift or the filling of cysts because CERASORB® alone has shown itself to be a suitable material for these applications. These results are supported by many publications including Hoch, Palti, Foitzik et al., Basa et al., Horch et al., Szabo et al. and Schermer.²⁻¹⁰

While the use of β -TCP to fill bone defects is now accepted, the need to use membranes in association with augmentation procedures is still controversial. In smaller procedures, where the mucous membranes are in good condition and the wound has been closed without tension, it may not be necessary to use a

membrane. Appropriate membranes should be used if wound dehiscence occurs, or is to be expected, and whenever additional protection seems helpful for undisturbed bone regeneration. Both resorbable (e.g. Osgide®) and non-resorbable membranes (e.g. PTFE membrane) are available depending on the indication and the aim of treatment. When choosing a membrane it is crucial that the indication and the technology are suitable for each other. Although the use of synthetic materials based on β -TCP can now be considered established, the "granular" form of the product was repeatedly criticised; this led to the development of products that were easier to handle and more user-friendly. CERASORB® Paste – the subject of this study – was developed to fill smaller defects. The main properties of this product can be summarised as follows. It is based on CERASORB® M Granules with their interconnecting pore system, which have been optimised in over 15 years of clinical use and serve as a mechanical framework for the formation of new bone. Parallely to the formation of new bone, the granular material is completely absorbed. Because of its entirely synthetic manufacture there is no risk of the immune reactions and infections that can occur with donor material of human or animal origin.

The paste can be completely and accurately applied directly from the sterile prefilled syringe to fill small bone defects. The syringe also makes it possible to use the material effectively in sites that are hard to reach. After complete filling of the defect the paste maintains optimal contact with the surrounding healthy bone. The hydrogel does harden during and after application. This means that the paste keeps its long-term plasticity when in the defect and its volume remains stable; it can fill the defect completely so that it is flush with the edge. After application the paste takes up growth factors by diffusion from the bony bed. In this process, the hyaluronic acid gel presents the incoming cells with a matrix through which the fine CERASORB® Granules can be made accessible. The result is early vascularisation and rapid formation of new bone.

The hyaluronic acid contained by the paste is a natural component of the extracellular matrix in humans. Because of the water-rich, plastic hydrogel structure of CERASORB® Paste, the growth factors, proteins and minerals that are needed for bone formation can be rapidly taken up without a diffusion barrier. The end-products of the metabolic process of bone formation are absorbed into the hydrogel or passed on to the surrounding blood-vessels and broken down by the body. According to the results of recent research, hyaluronic acid also stimulates the differentiation of stem cells into osteoblasts and has an anti-inflammatory effect.¹¹

Tab 4: After a total of 54–664 days
(mean: 342 days; median: 381
days).

Tab. 4: Final evaluation of defect filling/augmentation

Preoperative diagnosis	Bone augmentation / regeneration (n = 41)	Tolerability (n = 41)
Very good	21 (51.2 %)	24 (34.2 %)
Good	11 (26.8 %)	14 (58.5 %)
Satisfactory	3 (7.3 %)	0
Unsatisfactory	4 (9.8 %)	1 (2.4 %)
No answer	2 (4.9 %)	2 (4.9 %)

In two animal experiments (with rabbits) CERASORB® Paste was examined in detail in the distal femur and proximal tibia respectively. In both studies complete reconstruction of the bone structure was achieved in six months. There was no evidence of inflammation, allergy or a foreign body reaction, which indicates that the paste was well tolerated biologically.^{11,12} In another study (with sheep) CERASORB® Paste was used in a scapula defect. It was found that bone regeneration had occurred in the defects after six months and that the original bone structure with cortical bone and cancellous bone had been completely restored after twelve months. In all these studies both the β -TCP particles and the carrier substances were completely absorbed in parallel with the formation of new bone.¹³

If residues of CERASORB® particles are still visible on the X-rays, this is not automatically a sign of poor stability in the augmentation area or an absence of bone regeneration. It should always be remembered that an X-ray is a two-dimensional image of a three-dimensional space. Histologically it has been shown in many cases that the absorption of the granules and the rebuilding of autochthonous bone were much more advanced than was thought to be visible on the X-ray.

The main goal of this non-interventional study was to find out how the new product is applied and how it performs in standard dental procedures carried out by different users who are independent of each other. CERASORB® Paste proved to be an ideal synthetic bone regeneration material for the filling and augmentation of small dental bone defects; this material is absorbed while the body forms new bone of its own, as has already been reported by other authors.¹⁴ In 13 patients who took part in this non-interventional study, a total of 37 implants were placed, most frequently at #24, #26 and #14. 36 out of 37 implants were primarily stable. The bone quality at the time of implantation was judged to be optimal in twelve

of 22 cases, as good in six cases, as adequate in one case and as inadequate in three cases.

Summary

CERASORB® Paste is a new type of bone regeneration material in paste form based on fine β -TCP granules and hyaluronic acid matrix. In the present open multicentre study under everyday conditions this material showed itself to be suitable for filling smaller jaw defects, in particular because it is also easy to handle. It is noteworthy that no side effects of any kind and no intolerance reactions were observed.

Editorial note: This article was first published in DENTIMPLANTOL 21, 2, 84–89 (2017).



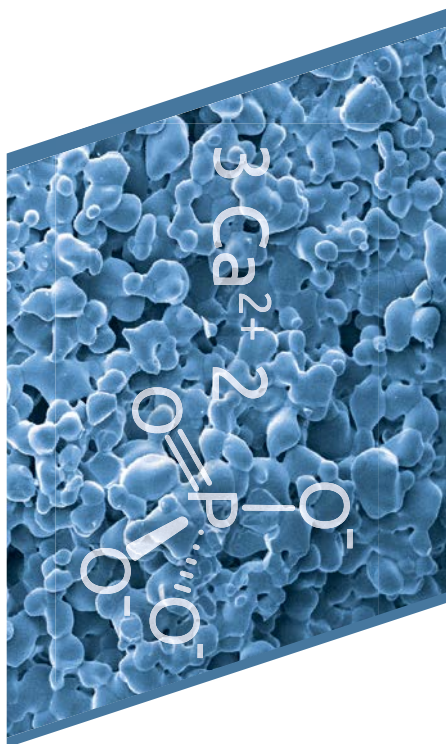
contact

Henriette Lerner

HL-Dentclinic
Ludwig-Wilhelm-Str. 17
76530 Baden-Baden
Germany
Tel.: +49 7221 39873-0
Fax: +49 7221 39873-10
info@hl-dentclinic.de

Author details





About curasan

curasan develops, manufactures and markets biomaterials and medical devices in the field of bone and tissue regeneration, wound healing and osteoarthritis therapy. As a pioneer and global technology leader in the growing field of regenerative medicine, curasan is specialized primarily on biomimetic bone grafting materials for dental, oral/maxillofacial, orthopedic and spinal applications, i.e. materials mimicking biological structures.

Numerous patents and a broad record of scientific publications demonstrate the clinical success of curasan's highly innovative products. Dental and orthopaedic clinicians worldwide benefit from the broad range of the premium quality and easy to use portfolio offered by the technology leader curasan.







curasan maintains its own high-tech facilities for research, development and manufacturing of biomaterials in Frankfurt/Main, Germany. In addition to its headquarters, the company has a subsidiary, curasan, Inc., in the Research Triangle Park area, near Raleigh, N.C., USA.

curasan's innovative products are cleared by the US Food and Drug Administration (FDA) and many other international authorities and available in almost 50 countries worldwide. curasan AG is a public company listed in the General Standard at the Frankfurt Stock Exchange.

Source: curasan AG





CERASORB® M Granules

Resorbable, pure-phase β -tricalcium phosphate

REF. No.	Size	Flip-off caps	Content	Packsize
9000 100 505	150–500 μ m		0.5 cc	5
9000 200 505	500–1000 μ m		0.5 cc	5
9000 201 001	500–1000 μ m		1.0 cc	1
9000 201 005	500–1000 μ m		1.0 cc	5
9000 202 005	500–1000 μ m		2.0 cc	5
9000 300 505	1000–2000 μ m		0.5 cc	5
9000 301 001	1000–2000 μ m		1.0 cc	1
9000 301 005	1000–2000 μ m		1.0 cc	5
9000 302 005	1000–2000 μ m		2.0 cc	5





CERASORB® Classic Granules

Resorbable, pure-phase β -tricalcium phosphate

REF. No.	Size	Flip-off caps	Content	Packsize
9002 200 505	500–1000 μ m		0.5 g	5
9002 300 505	1000–2000 μ m		0.5 g	5
9004 202 005	500–1000 μ m		2.0 g	5
9004 302 005	1000–2000 μ m		2.0 g	5


CERASORB® Plus Granules

Resorbable, pure-phase β -tricalcium phosphate

REF. No.	Size	Flip-off caps	Content	Packsize
9000 010 505	500–1000 μ m		0.5 cc	5
9000 010 105	500–1000 μ m		1.0 cc	5
9000 010 201	500–1000 μ m		2.0 cc	1
9000 020 205	1000–2000 μ m		2.0 cc	5

CERASORB® Perio Granules

Resorbable, pure-phase β -tricalcium phosphate

REF. No.	Size	Flip-off caps	Content	Packsize
9001 000 015	250–500 μ m		0.5 g	5

CERASORB® Paste

Resorbable β -tricalcium phosphate paste + hyaluronic acid matrix

REF. No.	Size	Content	Packsize
9001 304 041	$\approx 2 \text{ g} / \text{cm}^3$	0.5 cc	1
9001 304 051	$\approx 2 \text{ g} / \text{cm}^3$	1.0 cc	1

CERASORB® Mouldable Foam

Resorbable, pure-phase β -tricalcium phosphate + porcine collagen matrix

REF. No.	Size	Content	Packsize
9000 060 054	12 x 12 x 4 mm	0.5 cc	3
9000 060 124	25 x 12 x 4 mm	1.2 cc	1
9000 060 254	25 x 25 x 4 mm	2.5 cc	1
9000 060 504	25 x 50 x 4 mm	5.0 cc	1

Legend

Flip-off caps



silver



green hatched



blue hatched



green



blue



violet

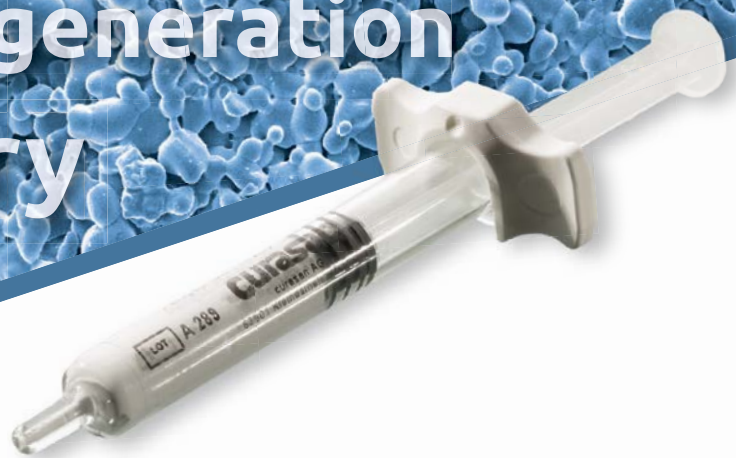Dental surgery

Oral and maxillofacial surgery

Periodontology

Bone regeneration

Dentistry



CERASORB®-Promise

CERASORB®. Keeps its words in bone regeneration.

CERASORB® M

- + big and microporous surface increases osteoconductivity
- + shortened duration of resorption by fast penetration with body own bone supporting structure

CERASORB® Paste

- + for immediate implantation in the filling and reconstruction of minor and multi-walled bone defects

CERASORB® Foam

- + easy handling thanks to defect-adapted modelling and comfortable positioning

Manufacturer:

curasan

curasan AG
Lindigstrasse 4
63801 Kleinostheim
Germany
cerasorb@curasan.de
www.curasan.de
Tel.: +49 6027 / 40 900 - 0
Fax: +49 6027 / 40 900 - 49

CERASORB® – Always First Choice.

