

Minimal invasive implantology with small diameter implants

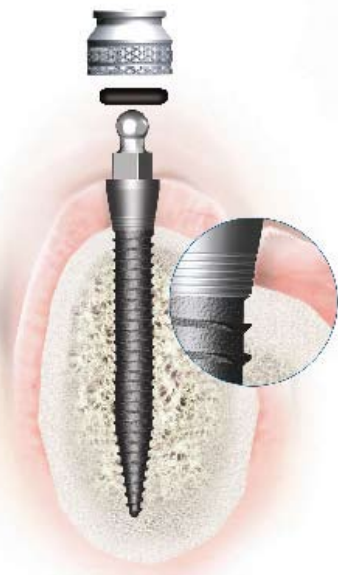
By Henriette Lerner

1. What are mini implants?
2. Macrodesign, microdesign
3. Anatomy of the atrophied maxilla and mandible
 - Bone quantity
 - Bone quality (density).
4. The philosophy of the system
 - Implant design
 - Insertion protocol
 - Immediate loading.
5. Indications for insertion
 - Removable restorations
 - Fix restorations.
6. Prosthetic restorations
 - Femovable prosthesis
 - Fix reconstructions.

1. What are mini implants?

The highest target in our profession is the fulfilment of patient wishes. The greatest wish of our patient is always the fast, painless replacement of their missing teeth or stabilisation of the prosthesis. A fast, stable and esthetic reconstruction of the patient's dento-facial system is the main goal of every dentist.

At the time, immediate loading was not an issue, the mini implants were used for the stabilisation of a provisional construction for the



time necessary for the osseointegration of the conventional implants. Those mini implants were 1.8mm to 3.3mm in diameter. This implant was also developed with a small ball on the top of it that could be incorporated as a snap for a denture, or to secure a temporary bridge. To uncover the standard implants, it was found that around 50% of the mini implants had actually integrated or bonded to the bone. In order to increase the rate of success, the implant design was improved in to follow the rules of osseointegration and the insertion protocol was changed to give the implants the primary stability necessary for immediate occlusal loading.

2. Macro and microdesign

a) Macrodesign

Design elements are affecting force transfer and osseointegration quality. The Imtec mini implants are one piece implants made by a Titanium Grade 5 alloy, and the implant body is threaded, with 'V' threads. The threaded design is used to maximise initial contact, improve initial stability, enlarge surface area and give the implant a favourable dissipation of force.

The macrodesign of the implants takes into consideration the biotype of the tissue. For thick soft tissue biotype, (>3mm) the implant has a collar with a smooth surface for the soft tissue integration. For the thin biotype is considered the implant with no collar.

The abutments are either a small ball or a conical (square head) abutment. The available implant diameters are 1.8mm, 2.1mm and 2.4mm (Figure 2). The rationalisation of using different implant diameters in different bone qualities will be discussed in one of the next chapters.

Implant lengths are: 10, 13, 15 and 18mm. In every diameter and every type the length of the implant is the length of the threaded part.

b) Microdesign

The surface of the implant is rough, the

microroughness is circa 150 micron, the nano-roughness is 20-30 microns. The roughness is gained through sand blasting and acid etching. The rough surface is conducive to the osseointegration after Bränemark.



Figure 1: (From left to right) Implants from O-ball to square head


3. Anatomy of the atrophied maxilla and mandible

a) Bone quantity

Tooth loss brings an atrophie of the processus alveolaris maxillae through the missing impulses from the level of the parodontal tissues and the missing turnover of the alveolar bone. Furthermore, systematic and hormonal and metabolic factors or local infections can negatively influence the quantity or quality of bone (Gruber et al, 1993; Ulm et al,1993).

In the first year after the tooth loss is 30-35% (Christensen et al) due to the reconstruction of the empty alveolar processes. The vertical bone loss continues on the processus alveolaris with cca 0.1mm every year and can reach sometimes 0.5mm (Atwood and Coy 1971; Tallgreen, 1972). The resorption of the maxillary bone is different as the one of the pars alveolaris mandibulae.

Atwood saw that the edentulous jaw resorbs in a certain way. Fallschlüssel (1986) made a classification of the resorbtion. Cawood and Howell (1988, 1991) modified it and the final form became the international classification for bone resorbtion (Figures 2 and 3):



Figures 2 (above) and 3 (below): RKL, classification of residual ridges Cawood & Howell (1988, 1991)



- RKL 1 – edentulous jaw, no resorption
- RKL 2 – empty alveola after extraction
- RKL 3 – healed alveola, processus alveolaris round and wide
- RKL 4 – high, narrow very thin Jaw
- RKL 5 – wide but vertically resorbed jaw
- RKL 6 – completely resorbed Jaw (same level with the palate).

b) Bone quality (density)

Dental implants are subject to masticatory loads of varying magnitude. Implant performance is closely related to load transmission at the bone-to-implant interface where bone quality will be highly variable. The type and architecture of bone is known to influence its load bearing capacity and it has been demonstrated that poorer quality bone is associated with higher failure rates. To date, bone classifications have only provided rough subjective methods for pre-operative assessment, which can prove unreliable. The results of an extensive analysis of computerised tomography scans using Iluma CT Scan demonstrate that an objective scale of bone density based on the Hounsfield scale, can be established and that there is a strong correlation between bone density value and subjective quality score ($P=0.002$) as well as between the bone density score and the region of the mouth ($P<0.001$).

The four macroscopic structures of bone were formulated first from Roberts and Frost.

After the classification of Misch and Judy,² bone density D1 is corresponding to a bone density of more than 1250 Hounsfield units.

D1 bone is primarily dense cortical bone, less spongiosa and is typical for the anterior region of the mandible. Tactile analog is an oak or maple wood.

Clinically, for the insertion of self-cutting,

compressive small diameter implants it is of a major importance the slow, careful insertion, in order to avoid necrosis and fractures.

D2 bone has dense-to-porous cortical bone on the crest and, within the bone coarse trabecular bone. Corresponding bone density is 850 to 1250 Hounsfield units. (Tactile analogy would be white pine or spruce wood). Anatomically, you can find it in the anterior region of the mandible, posterior region of the mandible and anterior maxilla. Clinically, important is a bi-cortical stabilisation of the implants, and an insertion protocol, which includes the penetration of the cortical bone solely.

In average it is one third of the length of the implant.

D3 bone types have a thinner porous cortical crest and fine trabecular bone in the region next to the implant. Similar with balsa wood. Anatomically is typical for the anterior or posterior region of the maxilla.

Clinically a bi-cortical stabilisation is absolutely necessary, and in the most of the cases because of less insertion torque than 35 Ncm, an immediate loading is not possible.

D4 bone has almost no crestal cortical bone. A fine trabecular bone characterises the region next to the implant. The typical region for this type of bone is the region of tuber maxillarae, the posterior region of the maxilla. This bone is for the insertion of the mini implants inadequate and contraindicated.

4. Philosophy of the system

An implant has a macroscopic body design and a microscopic component to implant design. Both implant designs are relevant for the clinical behaviour. The tapered design increases the compressive load at the interface. The macrodesign of the implant is different for the lower and upper jaw. The 1.8mm and 2.1mm diameter implants have a dense, V thread design, adapted to the dense bone design. (D1-D2).

The 2.4 mm implant has a thread design of reverse buttress, which gives the implant the possibility of very good stability at the insertion in regions with a low density of bone.

The microdesign is a rough surface (SLA and acid etched). The histological research shows an osseointegration after six months.³

Insertion technique

The insertion drill is 1.1mm. The drilling goes only through the cortical bone. The insertion in the spongiosa bone is through the self-cutting properties of the implant.

Inserting an implant of 1.8mm in a drill-

ing of 1.1mm bone compression will take place, similar to a bone condensing procedure through the osteotomes.

Through bone condensing, the bone quality (density) will change at the interface, in terms of a higher density.

The better the quality of the bone at the interface, the better the primary stability of the implant at the moment of the insertion. A stability of 35 Ncm is required in order to proceed an immediate loading on the implants (3).

A bi-cortical stabilisation increases the primary stability. (Figure 4)

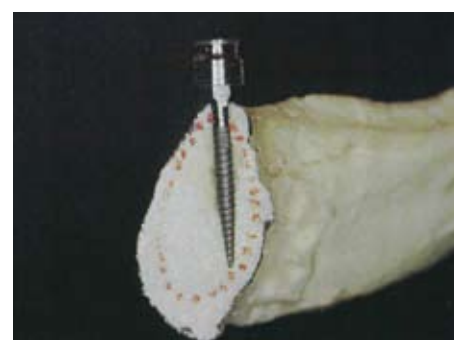

Figure 4: Bicortical implant stabilisation

5. Indication for insertion

The general indication for the placement of narrow diameter implants, ridges which, through resorption, become inadequate for placement of standard diameter implants: bucco-lingually $<5\text{mm}$, mesiodistally $<5\text{mm}$ or both.

The absolute indication will be completed in these cases where the patient does not want an augmentative bone reconstruction or is not indicated from the medical point of view.

a) Edentulous arches

The indication for the lower jaw is a 1.8-2.1mm diameter implant.

For the insertion of an implant with a diameter of 1.8-2.1mm we need 10mm bone height and 3mm bone width.

For the upper jaw the recommended implant is 2.4mm diameter. 4mm bone width and 10mm bone height will be needed.

b) Single tooth restoration

The second indication is the insertion of a mini implant in a small gap, in order to replace a front tooth or a premolar, in situations where the standard diameter implant is contraindicated or not possible. A small gap of mesio-distal dimension of 5 mm can be replaced with an implant of 2.4mm and a crown if the esthetical considerations will be adequate.

Implant planning

The number of implants recommended for the stabilisation of the full arch denture is at least four in the lower jaw and six in the upper jaw. The biomechanical considerations behind this rule are the surface of the BIC (bone-implant contact).

A BIC of two standard implants is circa 98.8 mm. For a long-term stabilisation, four mini implants of 1.8-2.1mm will be needed, in order to have a similar BIC. This consideration will give the long-term stability, which will be needed. For the same reason, at least six implants in the upper jaw are necessary.

A digital planning can be done and an insertion of the mini implants through a guide (Figures 5 and 6).

The planning can be made also with the help of a panoramic X-ray (Figures 7 and 8). The measurement of the width of the jaw will be made with a ridge caliper with flat active ends.

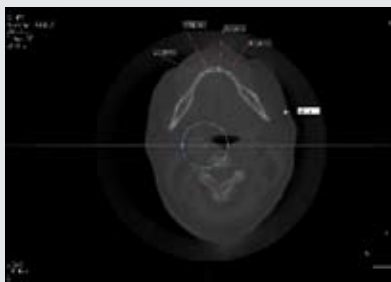


Figure 5: Bone width measurement on the IlumaCT

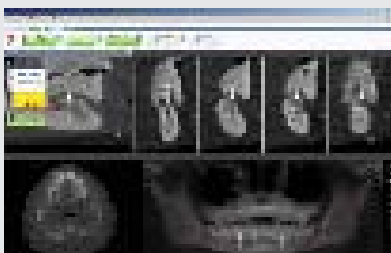


Figure 6: Mini implant planning on Iluma CT

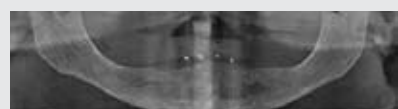

Figure 7: Panoramic X ray of the jaws with prosthesis and guthapercha points with 10mm distance inbetween

A ridge of less than 3mm will need a horizontal incision, in order to visualize the osseous crest. If the ridge width is 3 mm or more, a flapless procedure can be used.

The planning concerns the implant lengths and the placement of the implants in the ridge. The distances between the implants must be 10mm, in order to give enough place to the housings, considering also a certain degree of a possible deviation from a perfect parallel insertion.

The easiest way to plan a case is using gutta percha points in the prostheses or metal calibrated balls in a guide made above the prostheses. In the last case the distortion of the X-ray can be taken into consideration in the planning of the implant length, which will be planned with a measuring template with a distortion of 20% (Figure 5).

The primary stability of the implants (insertion torque 35Ncm) allows an immediate loading^{5,6}

The Implant placement in the maxilla will be planned and done similar (Figures 9-16).

In 98% of the cases done in the maxilla, an immediate loading was not possible. In this case a progressive loading will be done where the prosthesis will be spaciouly relieved around the O balls and filled with a soft layer (Secure soft Layer/Imtec). The patient will be instructed to consume soft food for the next 12-16 weeks. Histological research shows the osseointegration around minimplants after five months⁷. A well developed biological width with a large connective tissue was found.¹

Single tooth replacement with 2.9mm diameter implant (Figure 14). The absolute indication for this kind of narrow diameter implants, are:

- Replacement of a single tooth where the gap is 5-6 mm mesio distally (anterior lower incisor, premolar, anterior upper lateral incisor.)
- Replacement of a single or multiple teeth with crowns/bridges where the bone width (buccal - lingual dimension) is 5-6 mm
- Stabilisation of the upper and lower denture

with O ball system.

When inadequate bone is present for placement of standard diameter implants, most practitioners have been taught to suggest bone grafting, either using autogenous bone or one of the many available bone substitute materials. However, few patients desire to have, or can afford, bone grafting. The small diameter implants have the potential to assist in this challenge.

The insertion of an implant with conventional diameter (>3.5 mm) is not possible. Furthermore, another special indication is the immediate implant placement in the esthetic zone. Even if the conventional implant is correctly positioned, in a thin tissue biotype the buccal bone will resorb and a slight black transparency will occur with time so the esthetic result will be compromised. The solution is the insertion of a conventional implant very deep which will need a huge emergence profile so a bone resorbtion and tissue retraction at the gingival margin.

A better solution is a smaller diameter implant inserted in optimal position with an augmentation of the remaining buccal gap, which will assure a sufficient thickness of the labial plate.

The special design of the implant in the collar region gives, as the platform switching, a non surgical thickening of the tissue. Histologically, a stable biological width with along connective tissue was found.^{8,9}

The insertion protocol is made up of very few steps, which makes the system learnable and easy to use .

The philosophy of the insertion is depending on the bone density. The system needs two drills 1.1mm an 1.7mm diameter. Both drillings will have to penetrate the cortical bone, that means that in the mandible, the drilling will be approximately two thirds of the length of the implant, in the maxilla only approximately one third.

The complete insertion will be done through the self-cutting, self advancing comprehensive features of the implant.

The special micro design of the implant at the collar (microthreads, narrow neck) will give the stability of the bone at the shoulder of the implant during the loading¹⁰ and a well-defined biological width.

The temporary crown /bridge is made with a non-cemented snap-on cap. (Figure 19)

Thus the small diameter one piece-dental implant technique with auto-advance insertion into mature bone may provide treatment with minimal surgery, simplified implants, and less complex prostheses with resultant reduced trauma and reduced cost over present univer-




Figure 8 – Planning template considering a distortion of the X-ray of 20 – 25%

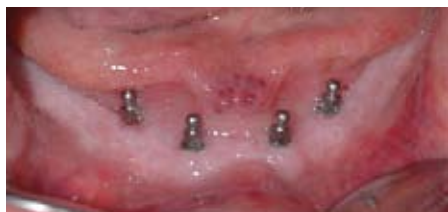

Figure 9: Implants immediately after insertion

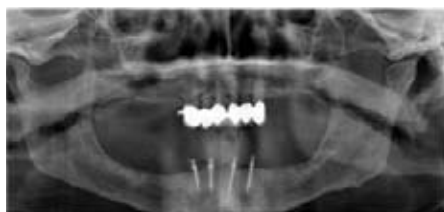

Figure 10: Four implants of 1.8 mm diameter and 13mm length after insertion

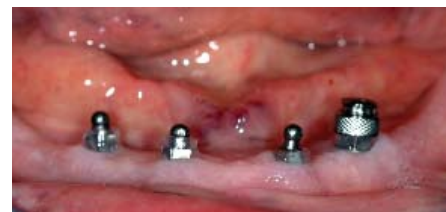

Figure 11: Direct procedure of integration of the housings in the prosthesis. Acrylic cylinders of circa 3mm height will isolate the undercutting places

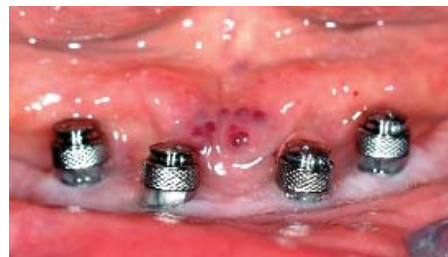

Figure 12: All the houses are in perfect position

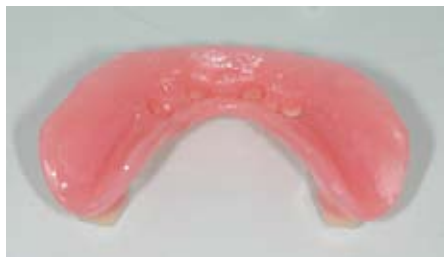

Figure 13: The prosthesis will be relieved for polymerisation of the housings

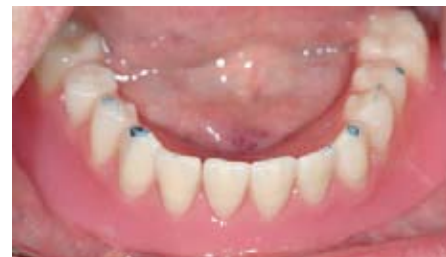

Figure 14: Insertion of the prosthesis with the Secure Hard Pick Up/Imtec. Prosthesis has to be in perfect occlusion

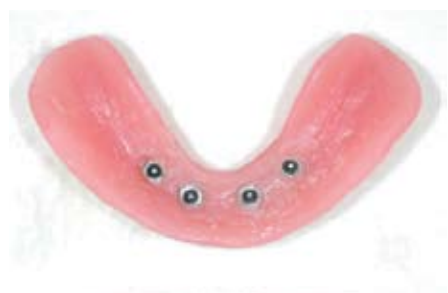

Figure 15: Integrated housings in polished denture

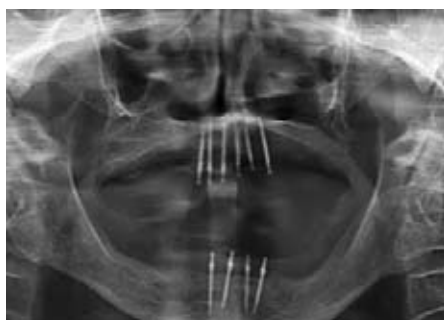

Figure 16: Radiograph of implants in situ



Figure 17: Design of a one-piece 2.9mm diameter implant

sally utilised implant treatment.

References

1. Roland Glauser, Peter Schüpbach, Jan Gottlow, Christoph HF Hämmerle. Peri-implant Soft Tissue Barrier at Experimental One-Piece Mini-implants with Different Surface Topography in Humans: A Light-Microscopic Overview and Histometric Analysis. *Clinical Implant dentistry and Related Research* 7: issue s1
2. Misch CE (1990). Density of bone: effect on treatment plans, surgical approach, healing and progressive bone loading. *Int J Oral Implant* 6:23-31
3. Todd Shatkin, Samuel Schatkin, Benjamin D Openheimer, Adam J Openheimer (2007). Mini Dental Implants for Long-Term Fixed and Removable Prosthetics: A Retrospective Analysis of 2514 Implants Placed Over a Five-Year Period. *Compendium* 28 (2): 36-41
4. Zeev Ormianer, Arun K Garg, Ady Palti (2006). Immediate Loading of Implant Overdentures Using Modified Loading Protocol. *Implant dentistry* 15: 1
5. Mi-Ra Ahn, Kyung-Mi An, Jung-Hwan Choi, Dong-Seok Sohn (2004). Immediate Loading With Mini Dental Implants in the Fully Edentulous Mandible. *Implant Dentistry* 13:4
6. Carl E Misch, Hom-Lay Wang, Craig M Misch, Mohamed Sharawy, Jack Lemons, Kenneth WM Judy (2004). Rationale for the application of immediate load in Implant dentistry. *Implant Dentistry* 13:3
7. Sahin S, Cehreli MC, Yalcin E (2002). The influence of functional forces on the biomechanical of implants-supported prostheses – a review. *J Dent* 30:271-282
8. Vigolo P, Givani A (2000). Clinical evaluation of single tooth mini-implant restorations: a five year retrospective study, *Journal of Orosthetic Dentistry* July, 84(1):50-4
9. Burto E Balkin, David E Stefik, Francine Naval (2001). Mini-dental implant insertion with the auto advance technique for onong applications. *Journal of Oral Implant* 27: 1
10. Carl E Misch, Jon B Suzuki, Francine M

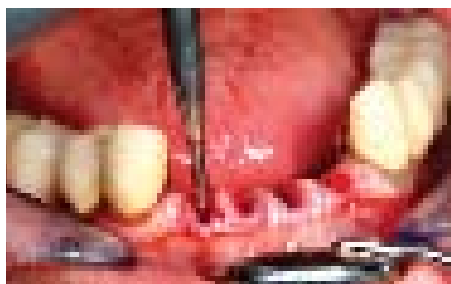


Figure 18: First drilling sequence

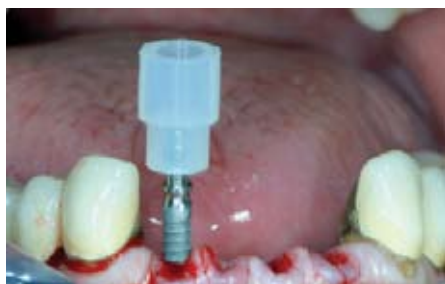

Figure 19: A 2.9mm one-piece implant insertion in a fresh extraction socket

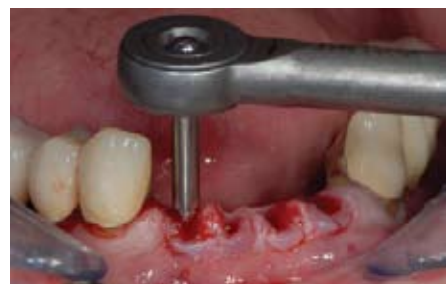

Figure 20: Insertion torque of 60 Ncm, an excellent primary stability of the implant

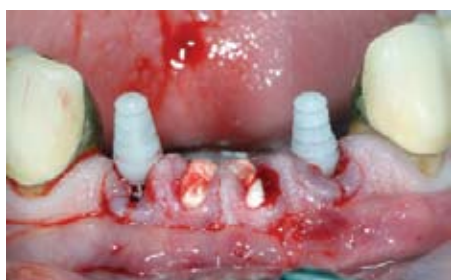

Figure 21: Insertion at the same level and augmentation of the remaining gaps




Figure 22: Temporary snap-on cap for not cemented temporisation

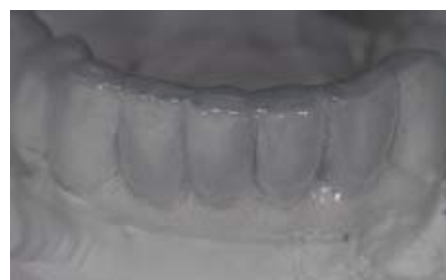
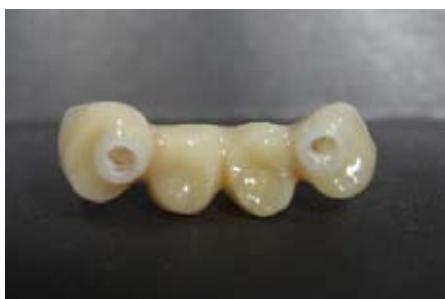
Figure 23: Template for temporary bridge




Figure 24: Immediate non-functional provisional made with template



Figures 25, 26 and 27: Temporary bridge on snap-on provisional caps will be snapped only on the implants at the period of optimum osseointegration (six months)

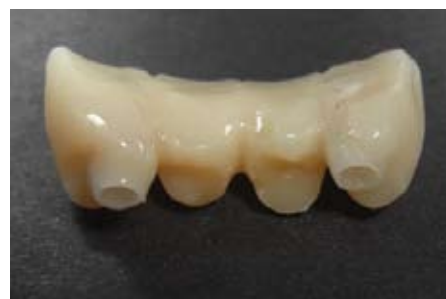

Figure 26:

Misch-Dietsh, artha W Bidez (2005). A Positive Correlation Between Occlusal Trauma and Peri-implant Bone Loss: Literature Support. *Implant Dentistry* 14: 2

11. Cornelis N Scheffler, H De Clerck, J Tulloch, C Behets. Systematic review of the experimental use of temporary skeletal anchorage devices in orthodontics. *American Journal of Orthodontics and Dentofacial Orthopedics*. 131 (4): S52-S58 M

12. Misch, Carl E; Hahn, Jack; Judy, Kenneth W; Lemons, Jack E; Linkow, Leonard I; Lozada, Jamie L; Mills, Edward; Misch, Craig M; Salama, Henry; Sharawy, Mohamed; Testori, Tiziano; Wang, Hom-Lay DOI: 10.1563/0722.1. Workshop Guidelines on Immediate Loading

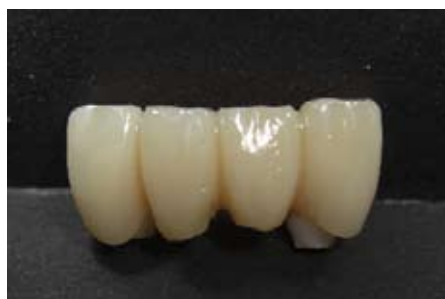

Figure 27:

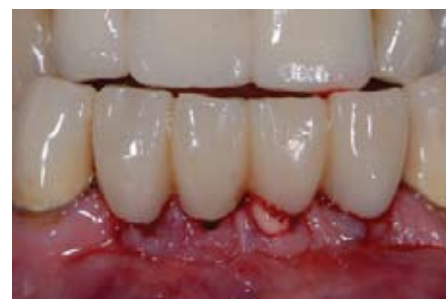

Figure 28 - Temporary bridge in non-occlusion

in Implant Dentistry. Journal of Oral Implantology Issn: 1548-1336. 30 (5): 283-288

13. Sendax VI (1995). Mini implants strategy offers a broad range of uses. Dent Today 14(1): 227-232

14. Mishal M, De Souza, Sabita M. Ram, Kartik Bhanushali. Dept of Prosthodontics, Pad Dr. D.Y. Patil Dental College and Hospital, Nerul Management of atrophic mandibular ridges with Mini Dental Implant system – A case report

15. Ron A Bulard (2003). Mini Dental Implants: Enhancing Patient Satisfaction and Practice income. Dentistry Today. 10: 7

16. Trevor McClain Griffiths, Chad Patrick Collins, Patrick Charles Collins, Spokane Wash. Mini dental implants: An adjunct for retention, stability, and comfort for the edentulous patient. Oral Surg Oral Med Oral Pathol Radiol Endod 100:E81-4

17. Ziv Mazor, Marius Steigmann, Roy

Leshem, Micahel Peleg (2004). Miniimplants to Reconstruct Missing Teeth in Severe Ridge deficiency and small Interdental Space: a 5 –year case series, Implant dentistry 13: 4

18. Campelo LD, Camara JR (2002). Flapless Implant surgery: a 10-year clinical retrospective analysis, Jomi Mar- April; 17(2):271-6

19. Chiapasco M, Gatti C, Rossi E, Haefliger W, Markwalder TH (1997). Implant-retained mandibular overdenture with immediate loading. A retrospective multicenter study on 226 consecutive cases. Clin Oral Implants Res 8:48-57

20. Sang-Choon Cho, Stuart Froum, Chih-Han TAI, Young Sung Cho, Nicolas Elian, Dennis Tarnow. Immediate loading of narrow diameter implants with overdentures in severely atrophic mandibles. Pract Proced Aesthet Dent Apr; 19 (3):167-74

21. Misch CE (1993). Patient force factors. In: CE Misch, ed. Contemporary Implant Dentistry. St. Louis, MO: CV Mosby

22. Adell R, Lekholm U, Rockler B, Branemark PL (1981). A 15-year study of osseointegrated implants in the treatment of the edentulous jaw. Int J Oral Surg 10(6):387-416

23. Branemark PL (1983). Osseointegration and its experimental background. J Prosthet Dent 50(3):399-410

24. Dessem D, Taylor A (1989). Reflex effects of periodontal mechanoreceptors on trigeminal motoneurons. In Van Steenberghe D, DeLaat A (eds): Electromyography of Jaw Reflexes in Man. Leuven, Belgium: Leuven University Press 177-196

ADVERTISER INDEX

ADVERTISER	PAGE	(RSC)
MiS Implants	2	(2)
Sirona	5	(5)
Nobel Biocare	7	(7)
Materialize	15	(15)
IMTEC	17	(17)
Zest Anchors	23	(23)
3D-Diagnostics	25	(25)
Astratech	39	(39)
i-CAT	43	(43)
E-WOO	63	(63)
Practiceworks	64	(64)

